

Minimally invasive vertical preparation design for ceramic veneers: a multicenter retrospective follow-up clinical study of 265 lithium disilicate veneers

Mario Imburgia, DDS

Private Dental Practice

Visiting Professor, Master of Prosthodontic Sciences, University of Siena

Active Member, Italian Academy of Prosthetic Dentistry (AIOP)

Board Member, Digital Dentistry Society (DDS)

Davide Cortellini, DDS, DMD

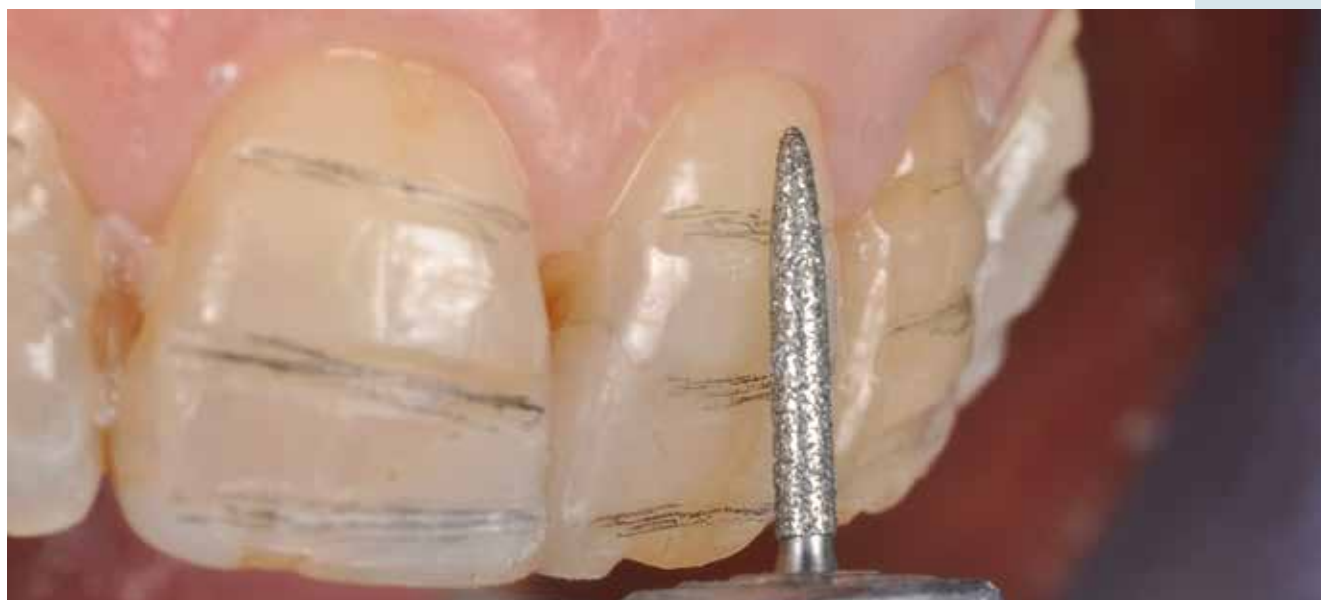Private Dental Practice

Active Member, Italian Academy of Prosthetic Dentistry (AIOP)

Marco Valenti, DDS

Prosthodontist Studio Valenti

Active Member, Italian Academy of Prosthetic Dentistry (AIOP)



Correspondence to: **Dr Mario Imburgia**

Advanced Dental Center, Via Speronari 6, Milano, 20123 Italy; Tel: +390916253662; Email: marioimburgia@yahoo.it

Abstract

The esthetic treatment of the anterior teeth has always presented a challenge in clinical practice. With the improvement of dental materials, many restorative options such as resin composites, all-ceramic crowns, and ceramic veneers have become available. The current challenge in reconstructive dentistry is how to obtain excellent esthetic results while preserving the biological structures involved as much as possible. Thanks to the introduction of high-strength etchable dental ceramics, clinicians and technicians now have materials and procedures at their disposal that allow for the restoration of esthetics and function through a minimally invasive approach. New-generation, all-ceramic restorations and adhesive systems allow greater preservation of residual hard tooth structures, especially with regard to single elements.

Purpose: To evaluate the clinical performance of lithium disilicate (LiDiSi) veneers with a feather-edge finish line margin.

Materials and methods: A total of 265 LiDiSi veneers were cemented with resin cement after fluoridric acid and silane surface treatment and observed by different clinicians. These veneers were placed in 53 (32 female, 21 male) patients between October 2009 and April 2015, with a mean observation period of 54.4 months. Of these, 211 veneers were placed in the maxilla (77 central incisors, 65 lateral incisors, 49 canines, 12 first bicuspid, 5 second bicuspid, 2 first molars, 1 second

molar), and 54 in the mandible (16 central incisors, 14 lateral incisors, 13 canines, 6 first bicuspid, 1 second bicuspid, 2 first molars, 2 second molars). The clinical evaluation used the modified California Dental Association (CDA) and Ryge criteria after recalling all patients between January and March 2017. The clinical parameters evaluated were color matching, quality of the ceramic surface, the presence of marginal discoloration, and marginal integrity. The data were analyzed through descriptive statistical analysis.

Results: The clinical survival of the 265 veneers over the follow-up period was 99.63%. One restoration showed adhesive failure due to a traumatic event after 3 years of clinical service. The color matching parameter was classified as Alfa in 93.9% (248/265) and Bravo in 6.4% (17/265) of the restorations, with no Charlie or Delta ratings recorded. The ceramic surface was rated as Alfa in 97.7% (259/265) and Beta in 2.2% (6/265), marginal discoloration as Alfa in 97.3% (257/265) and Beta in 3% (8/265), and marginal integrity as Alfa in 96.9% (256/265) and Beta in 3.4% (9/265) of the restorations.

Conclusion: In this retrospective analysis, LiDiSi veneers with a vertical finish line showed good clinical performance in terms of color matching, ceramic surface, marginal discoloration, and marginal integrity. Despite the present results, further clinical studies are needed in order to investigate the long-term performance of this type of restoration.

(Int J Esthet Dent 2019;14:2–14)

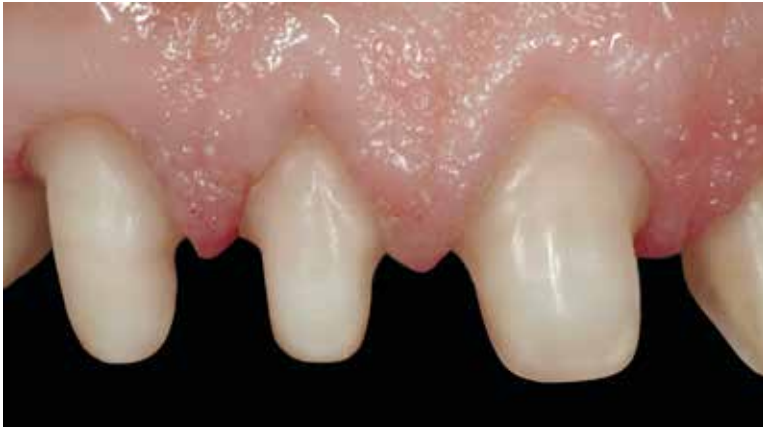

Fig 1 Horizontal preparation.

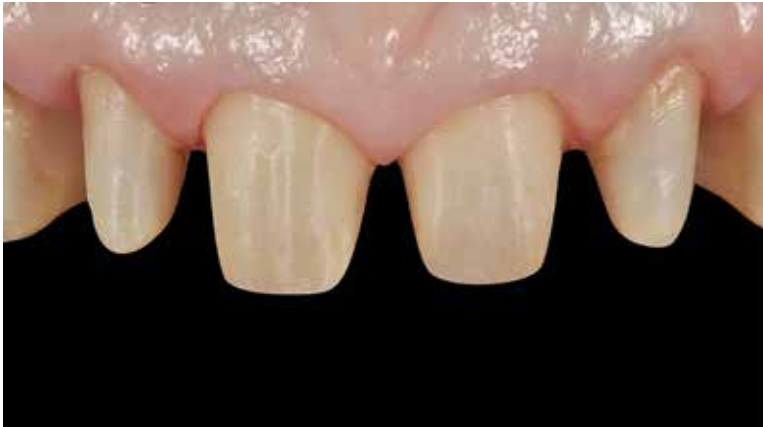

Fig 2 Vertical preparation.

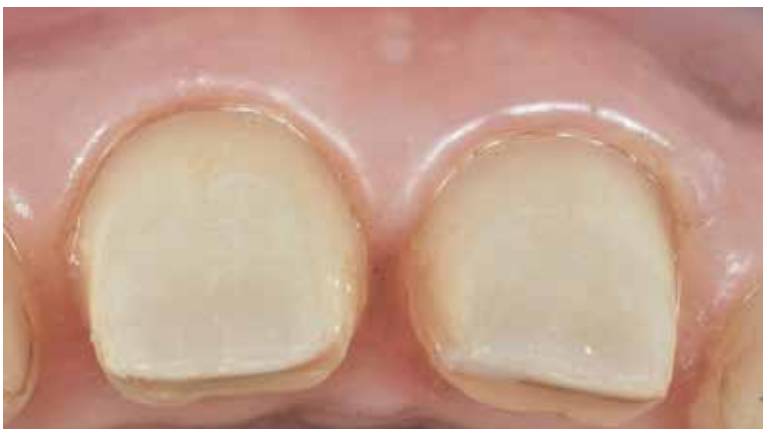

Fig 3 Occlusal view of a vertical preparation.

Introduction

Porcelain laminate veneers (PLVs) are a minimally invasive esthetic restorative option with a high long-term success rate. This treatment option has been used due to its color stability, biocompatibility, mechanical properties, and good esthetic outcome.¹⁻⁴ For successful dental restorations, a minimally invasive approach is essential. Thus, minimum-thickness, full-ceramic restorations have been increasingly indicated.⁵⁻¹³

Lithium disilicate (LiDiSi) ceramic used in its monolithic form, individualized with a staining technique, represents a material that is particularly suited to situations of erosion or abrasion where it is necessary to replace or restore damaged enamel through a 're-enameling' process.¹⁴⁻¹⁶ It is also suitable for the prosthetic correction of malpositioned or diastematic teeth as well as for restoring teeth that are incongruous in shape or color due to extended, poor-quality composite fillings. IPS Empress 2 and the newer brand IPS e.max (both Ivoclar Vivadent) are LiDiSi-based ceramics. LiDiSi is a heat-pressed or computer-aided design/computer-aided manufacturing (CAD/CAM) ceramic with a crystalline phase consisting of LiDiSi and lithium orthophosphate, which increases resistance without negatively influencing translucency. It has a biaxial flexural strength of 407 ± 45 MPa. This material is used to manufacture high-strength cores for porcelain-supported or monolithic restorations.

The tooth preparation indicated by manufacturers for metal-free restorations has traditionally been a horizontal preparation with a well-defined margin: chamfer, shoulder, or a slight chamfer (Fig 1). To define a tooth preparation without a defined finish line, terms such as knife-edge, feather-edge, shoulderless (or more simply, vertical) are used, differentiating the preparation from the typical horizontal chamfer or shoulder

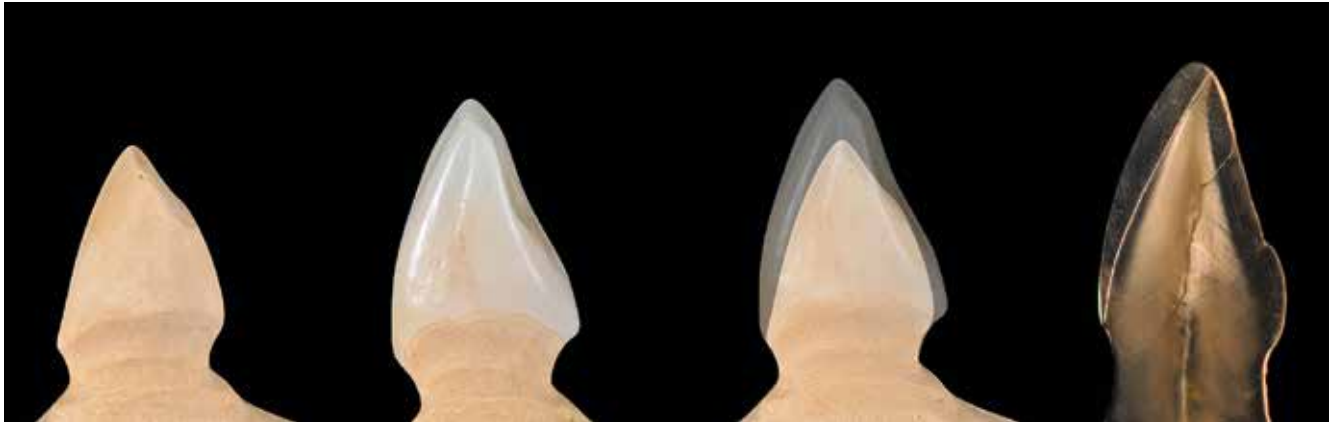


Fig 4 The adhesive ceramic restoration artificially mimics the layering of natural teeth (image courtesy of Dr J. Manauta).

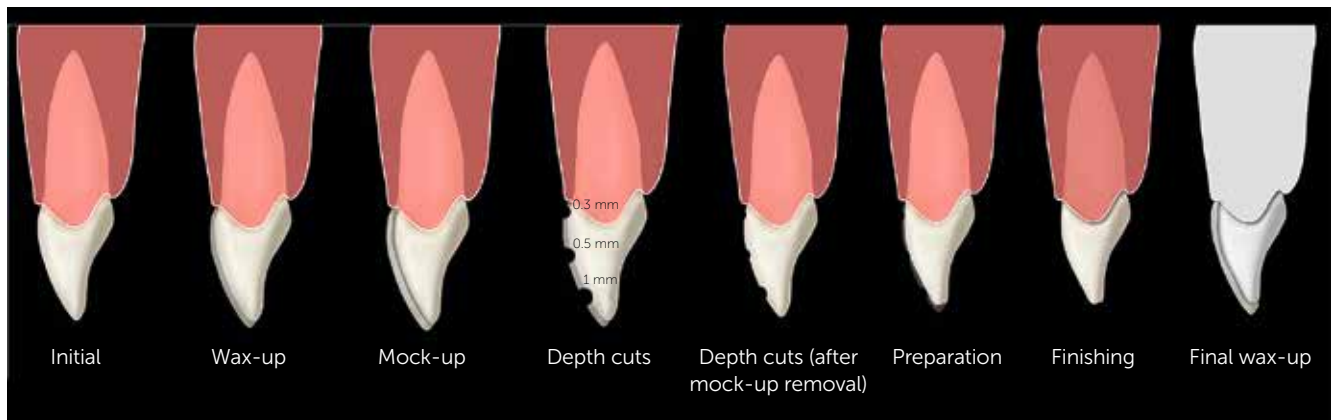


Fig 5 The workflow of the preparation procedure.

(Figs 2 and 3). The vertical preparation is classically indicated for perioprosthodontic rehabilitations¹⁷ and metal-ceramic restorations. In contrast, little has been published on the use of all-ceramic crowns with a feather-edge preparation.¹⁸⁻²⁰ Although the horizontal preparation has always been the margin of finish typically indicated for glass-ceramics, these materials have also been used with a horizontal preparation in an 'unconscious' manner by some clinicians. We refer here to the additional ceramic restorations that exploit the opportunity to cement adhesively etchable dental ceramic to the tooth structure. Such restorations, by their nature, often have a very thin

margin, similar to a feather-edge margin. These additional restorations are often made with feldspathic ceramics, which have poorer biomechanical characteristics than LiDiSi.

The combination of LiDiSi and a vertical preparation²¹ is, in the opinion of the present authors, the most conservative approach possible in prosthetic dentistry: a high-strength, etchable ceramic that can be used at minimum thickness, and a vertical tooth preparation with maximum preservation of dental substance, especially in the cervical area (Fig 4).

The aim of the present study was to evaluate the clinical performance of LiDiSi heat-

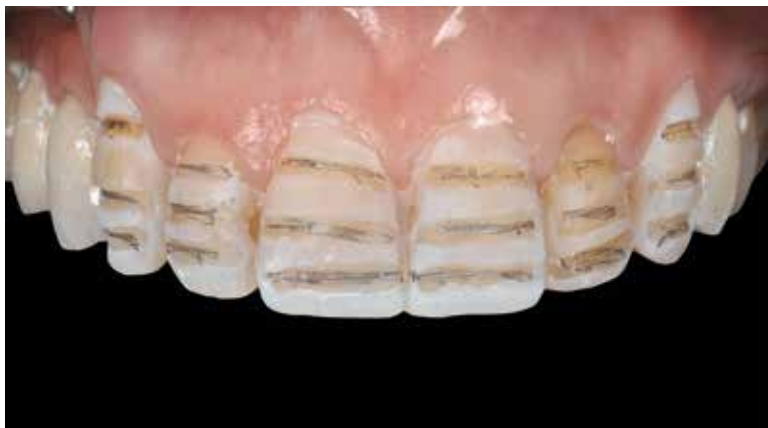

Fig 6 Preparation through the simulation of the final restoration is a key element of this procedure.

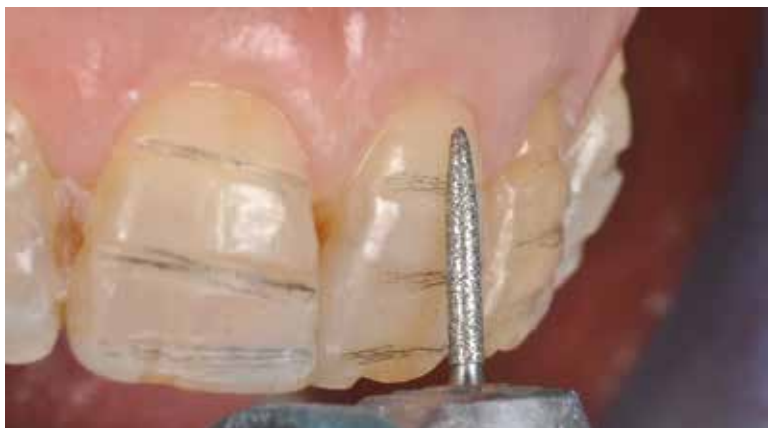

Fig 7 The vertical preparation aims to maximize tissue preservation.

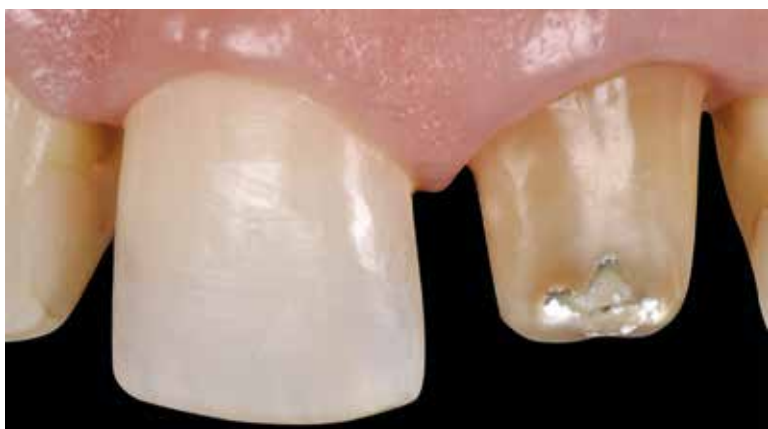

Fig 8 The same finish margin could be used in combined veneer and crown restorations.

pressed veneers with knife-edge margins placed in a private dental practice environment.

Materials and methods

Since this is a retrospective study, no approval was requested from the ethics committee in accordance with the National Code on Clinical Researches.^{22,23}

In this study, in the common context of general practice, three different clinicians treated 53 patients (32 female, 21 male) with 265 LiDiSi veneers with a knife-edge preparation. The patients were recalled for professional oral hygiene treatment every 3 to 6 months, depending on their periodontal condition at the beginning of the treatment.

The teeth were prepared with a vertical finish line and an overall reduction from 0.2 to 1 mm for the incisal surfaces. The thickness of the preparation was performed according to the final volume of the restoration (Figs 5 to 7). Provisional restorations were manufactured using a silicone index technique and cemented using a spot-etching technique. During the preparation and finishing procedure, the preservation of tooth structure was maximized (Figs 8 to 12).

During the same clinical session of tooth preparation, a single retraction cord (Ultrapack; Ultradent and Sil-Trax; Pascal) technique was used before the final impression was made with a polyether material (Impregum Penta; 3M ESPE) using a single-impresion, double-mixing technique with a standard tray. The cord size was based on the depth of the gingival sulcus. A full-arch, irreversible, hydrocolloid impression (Algino-plast; Heraeus Kulzer) was made of the opposing dentition and poured immediately with type IV dental stone (GC Fujirock EP; GC America).

All the veneers were fabricated according to the manufacturer's instructions (Fig 13).

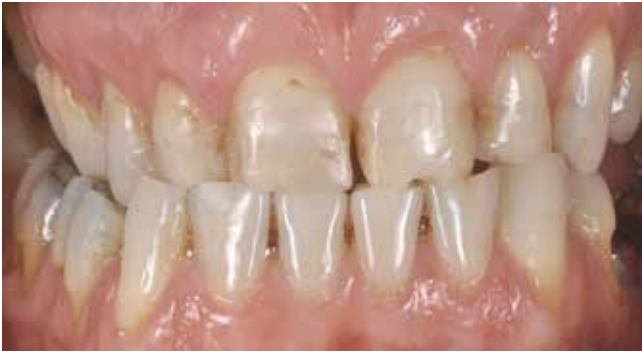

Fig 9 The vertical preparation applied in a full-mouth rehabilitation.

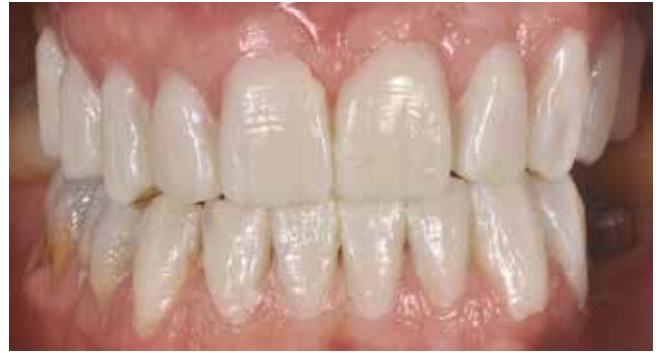

Fig 10 The final volume of the ceramic restorations is shaped to achieve an increase in the vertical dimension of occlusion when it is needed.

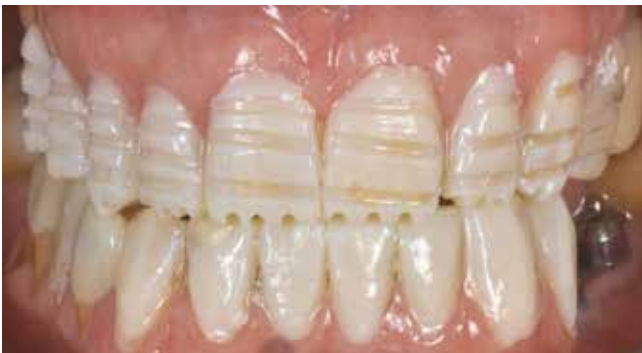

Fig 11 Calibrated preparation could be performed in the same clinical session.

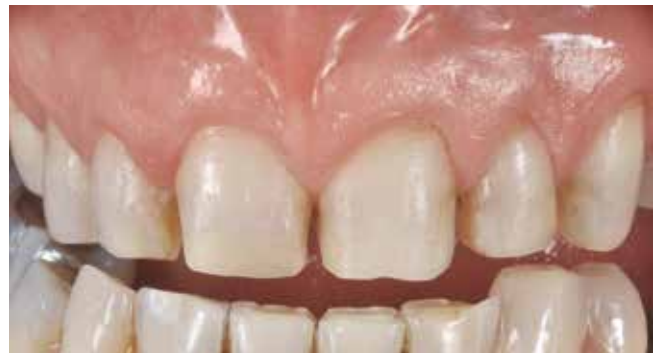

Fig 12 The final vertical preparation.

The manufacturer gave the authors a positive opinion on the use of the investigated finish line in the case of veneer restorations.

Each veneer was assessed for proximal contacts, occlusal relationships, shade matching, and marginal adaptation. Small occlusal adjustments were made before luting, where necessary, and the final occlusion was checked after cementation using cone-shaped burs with grit sizes of 100 and 125 μm .

Cementation was performed without rubber dam by two of the clinicians, and the operative field was isolated with retractors (OptraGate; Ivoclar Vivadent), high-velocity evacuation, silicone, and Teflon tape. The third clinician preferred to use rubber dam during cementation. The restorations were etched with 5% hydrofluoric acid (Porcelain Fix; BJM Lab) for 20 s,

washed, and rinsed with water, then dried and silanized with Monobond-S (Ivoclar Vivadent). The prepared tooth was treated with a three-step adhesive system when a large amount of residual enamel was required, otherwise a dentin self-etching primer was used. Depending on the final thickness of the restorations, a light-curable resin cement (Variolink Veneer; Ivoclar Vivadent) or a dual-polymerizing resin cement (Multilink Automix; Ivoclar Vivadent) was used.

Initial light polymerization was performed for a few seconds. Any excess cement was removed from the buccal and interproximal surfaces with a dental probe, dental floss, and a double-edged blade (surgical scalpel blade No. 12D; Swann-Morton). The final polymerization was performed for 3 min with a halogen curing light at 780 mW/cm^2 (Optilux 501; Kerr). The occlusion

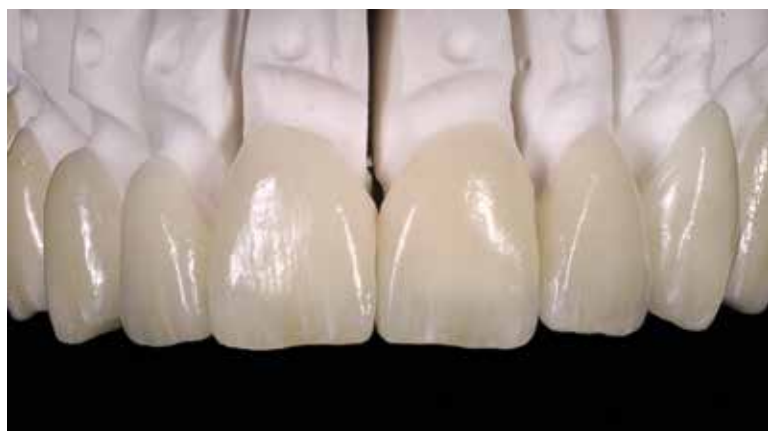

Fig 13 The pressed LiDiSi ceramic veneer on the master cast.

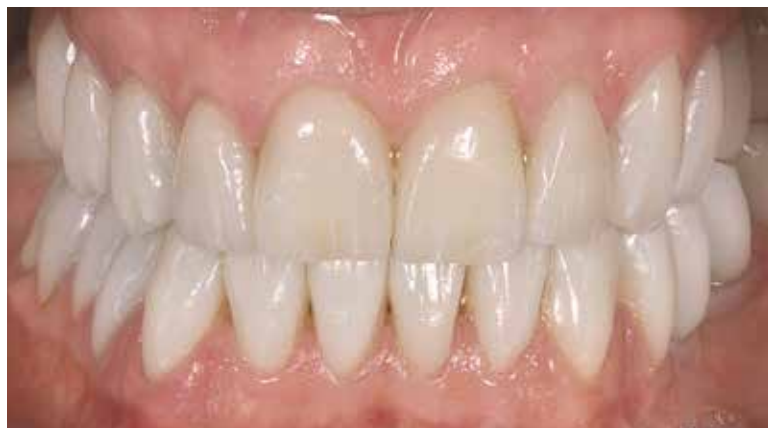

Fig 14 The ceramic restorations 48 h after luting.

was refined where needed, and any adjusted crown surfaces were polished. Final occlusal adjustments were performed with egg-shaped burs (grit size 125 μm). The ceramic surface was then polished with silicone discs (Ceramic polisher 9545 F; Braseler) and felt wheels using polishing paste (Dia Glace diamond paste; Yeti) (Fig 14).

Infiltration due to abutment decay, core fracture, or partial or complete debonding that exposed the tooth structure were the main criteria for failure.

The first evaluation was performed at the time of cementation (baseline), with reevaluations being made once every 3 to 6 months thereafter during routine professional hygiene appointments (Figs 15 to 17). Every examination was performed using an intraoral mirror, a sharp explorer, a periodontal probe (XP23/OW; Hu-Friedy), radiographs (once a year), and, in some cases, photographs.

All the patients were recalled between January and March 2017. The veneers were evaluated for apparent changes in their outward structural integrity (chips, cracks, fractures) and marginal integrity using a sharp dental explorer, in accordance with the modified California Dental Association (CDA) and Ryge criteria. The analysis was always performed by a different clinician working in the same practice. For failed restorations, the examiner tried to determine the cause of failure.

Results

In this retrospective study, the clinical performance of feather-edge, LiDiSi veneers placed in a general practice environment was evaluated. LiDiSi veneers had a survival rate of 99.63%. A total of 211 veneers were placed in the maxilla (77 central incisors, 65 lateral incisors, 49 canines, 12 first bicuspid, 5 second bicuspid, 2 first molars, 1 second molar) and 54 in the mandible (16 central incisors, 14 lateral incisors, 13 canines, 6 first bicuspid, 1 second bicuspid, 2 first molars, 2 second molars).

One adhesive failure was recorded after 3 years of clinical service after a traumatic event. This complication was managed by cleaning the intaglio surface of the veneer and the tooth surface, then luting the restoration again. The clinical survival of 265 LiDiSi veneers placed in 53 patients over a mean observation period of 54.4 months (with veneers in service between 24 and 105

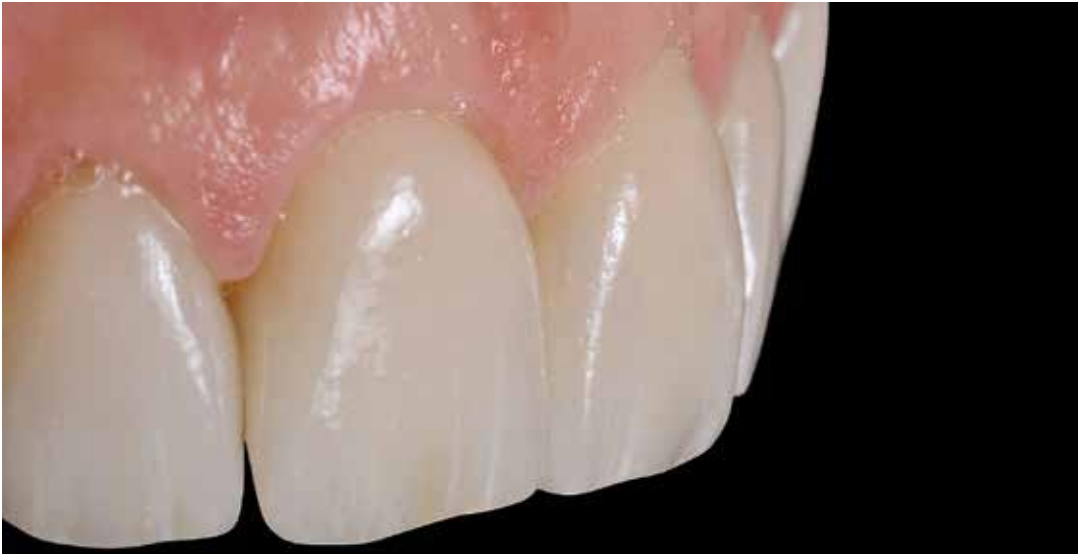

Fig 15 Follow-up.

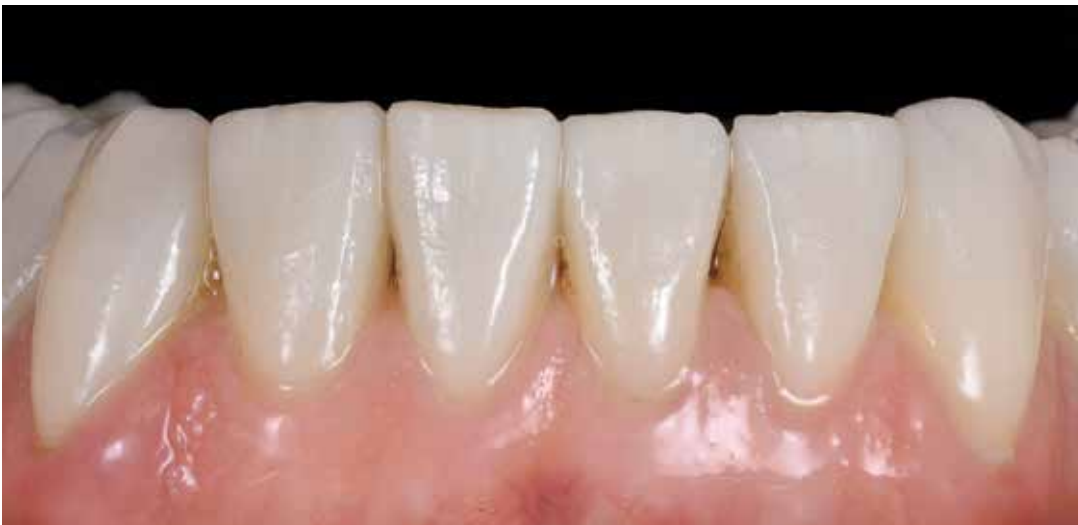

Fig 16 Follow-up.

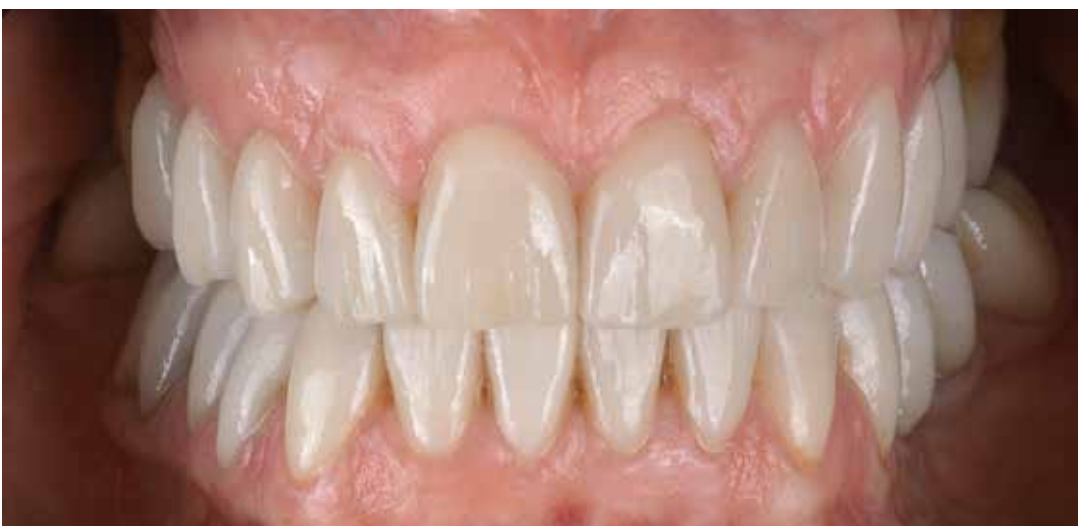

Fig 17 3.5-year follow-up.

Table 1 Follow-up periods for different veneer locations

Veneer locations and follow-up time																											
T	1.1	1.2	1.3	1.4	1.5	1.6	2.1	2.2	2.3	2.4	2.5	2.6	3.1	3.2	3.3	3.4	3.5	3.6	3.7	4.1	4.2	4.3	4.4	4.5	4.6	4.7	
24	1	1	1				1	1	1																		
27	1	1	1				1	1	1				1														
33	2	2	2				1	2	2																		
34	1	1	1	1	1		1	1	1	1	1		1	1	1	1				1	1	1	1				
35			1	1				1	1		1																
36	2	2	2	1			2	2	2	1			1	1	1	1				1	1	1	1				
37	2	2	1				3	2	1																		
38	1	1					1	1					1	1													
39	1	1	1				1	1	1																		
41	1	1					1	1																			
44	1	1	1				1	1	1																		
46	3	2	2				3	2	2																		
49	1						1																				
50							1	1																			
51	1	1	2	2	1	1	2	2	2	1	1	1			1	1	1	1	1				1	1		1	1
52	1	1	1				1	1	1																		
53		1	1					1	1																		
56									1																		
57	2	1					3	2					1	1	1					1	1	1					
60	1	1	1				1	1	1																		

months) was studied between January and March 2017 (Table 1).

The modified CDA and Ryge criteria were recorded in this investigation to assess color matching, quality of the ceramic surface, presence of marginal discoloration, and marginal integrity. The evaluation of color matching was classified as Alfa according to the modified CDA and Ryge criteria in 93.9% (248/265) and Bravo in 6.4% (17/265) of the restorations, with no Charlie or Delta ratings recorded. The ceramic surface was rated as Alfa in 97.7% (259/265) and Beta in 2.2% (6/265), marginal discoloration as Alfa in 97.3% (257/265) and Beta in 3% (8/265), and marginal integrity as Alfa in

96.9% (256/265) and Beta in 3.4% (9/265) of the restorations (Table 2).

Discussion

In this retrospective study, the clinical performance of feather-edge LiDiSi veneers placed in a general practice environment for up to 105 months with a mean observation period of 54.4 months was investigated. The cumulative survival rate was 99.63%. This survival rate is comparable with the results of the studies by Aykor and Ozel (2009),¹² Guess and Stappert (2008),³⁴ Fradeani et al (2005),¹¹ and Fradeani 1998,³⁵ which investigated the survival rate of heat-

Veneer locations and follow-up time																										
T	1.1	1.2	1.3	1.4	1.5	1.6	2.1	2.2	2.3	2.4	2.5	2.6	3.1	3.2	3.3	3.4	3.5	3.6	3.7	4.1	4.2	4.3	4.4	4.5	4.6	4.7
61													1	1	1					1	1	1				
62							1																			
65	1	1	1	1									1	1						1	1					
66	1	1					1	1																		
69	1	1					1	1	1																	
70	1						1	1																		
72	2	2	1	1			2	2	1																	
73													1							1						
76							1																			
77			1						1																	
80	1	1	1	1			1	1	1	1																
81	1	1																								
84							1																			
87	1	1	1				1	1	1																	
88							1																			
94	1	1					1	1													1	1				
97	1	1					1	1																		
98	1	1	1				1	1	1																	
99	1						1						1	1	1					1	1	1				
105	1																									

T: Time (in months)

Table 2 Data referring to the final check between January and March 2017 according to the modified CDA and Ryge criteria

Clinical rating for the 265 LiDiSi veneers				
	Alfa	Bravo	Charlie	Delta
Color matching	248	17		
Ceramic surface	259	6		
Marginal discoloration	257	8		
Marginal integrity	256	9		

pressed ceramic veneers with a traditional preparation.

In the present investigation, 93.9% of veneers received the highest rating (Alfa) for color matching. Only 6.4% received a Bravo rating; the lack of optimal color matching in these cases was probably due to the ultra-conservative preparation, even in severely discolored teeth. Indeed, when the same ingot is used to press all the restorations for the same case, a single or a few discolored teeth could affect the final perfect color matching of the restorations.

The quality of the ceramic surface was given the highest rating in 97.7% of the restorations. Pressable systems have higher strength and fracture toughness than powder/liquid systems (porcelain) due to their lower porosity and higher concentration of crystals.³⁶

All the ceramic restorations were perfectly polished by the dental laboratory, and only in the case of occlusal adjustments was postcementation polishing performed. The marginal discoloration and marginal integrity evaluation showed slightly better results, probably because the feather-edge design with less tooth preparation exhibited smaller marginal openings compared with the traditional preparation technique, which presented microleakage after 5 years in 9% of restorations.³⁷⁻³⁹

Marginal discoloration events that received a Beta score were recorded in 3% of restorations, a significantly better result compared with the recorded 9.5% of cumulative 5-year rates weighted in the systematic review published by Petridis et al in 2012.³⁷ The marginal discoloration rate is similar to the data presented by Morimoto et al³⁸ in their systematic review, probably due to the more conservative preparation approach of the included studies. Compared with the overall cumulative survival rate in other clinical studies, the present authors found better clinical performance of glass-ceramic

veneers (94%) and feldspathic porcelain veneers (87%).³⁸

Preparation through the mock-up and the absence of a marginal chamfer or shoulder allows the clinician to preserve the enamel even in the cervical area, the most critical zone.^{3,4,33}

Several studies have shown a relationship between fracture of the ceramics and insufficient thickness of the restoration;²⁴⁻²⁶ on the other hand, deep preparation that exposes a large amount of dentin could expose the restoration to an increased risk of debonding and microleakage.²⁷⁻³³ Ceramics with a vitreous phase, which allow bonding, demand less dental preparation. The larger the amount of tooth preserved, the smaller the deflection of the tooth, and this could explain the absence of failure in the short and medium terms. The tooth–ceramic interface becomes very strong after adhesive cementation, reinforcing the ceramic and restoring the strength of the tooth.⁴⁰

While LiDiSi crowns have been tested with shoulderless preparations, no data are available on the use of a vertical finish line margin on veneers, either clinically or *in vitro*. Only two previous articles reported the use of feather-edge tooth preparation with LiDiSi in full-crown restorations. The results of our analyses are similar to the data published by Cortellini in 2012,¹⁹ and Valenti and Valenti in 2015.²⁰

A vertical tooth preparation combined with a LiDiSi restoration represents the maximum preservation of dental substance because of the limited thickness of the crown in the cervical area, and, thanks to the translucency of LiDiSi, allows for the minimization of restoration thickness without influencing resistance.

The slight overcontour present at the margin of the restoration is not a periodontal health-risk factor because this approach recreates an artificial cemento-enamel junction, where the all-ceramic crown replaces

the enamel with a stable gingival level and with no sign of inflammation.^{19,20}

The success rate of the restorations achieved in the present study was probably influenced by the flexural strength of LiDiSi, and a minimally invasive preparation with the highest degree of enamel preservation, not only on the margins but also on the tooth surface. Only one failure was recorded after 3 years of clinical service. The clinician who had performed this restoration had performed a cementation using rubber dam. The static and dynamic occlusal contacts were correct (achieving the contact on the palatal tooth structure in the maximum intercuspation position and avoiding any interference during protrusive and lateral movement), so the failure was probably due to a traumatic event (the patient was

chewing a sweet and came across an unexpected seed inside it) rather than an adhesive failure.

Conclusions

The clinical performance of LiDiSi with feather-edge margins, shown in this retrospective analysis, suggests that this approach achieves similar results to those reported for other margin designs or different kinds of restorations, allowing for very conservative tooth preparation and an excellent esthetic outcome. Although the survival analysis of this study is a useful reference regarding the medium-term capabilities of LiDiSi used in vertical tooth preparations, longer-term randomized controlled clinical trials should also be conducted.

References

- Dietschi D, Spreafico R. *Adhesive Metal-Free Restorations: Current Concepts for the Esthetic Treatment of Posterior Teeth*. Chicago: Quintessence, 1997.
- Chen JH, Shi CX, Wang M, Zhao SJ, Wang H. Clinical evaluation of 546 tetracycline-stained teeth treated with porcelain laminate veneers. *J Dent* 2005;33:3–8.
- Gürel G. Predictable, precise, and repeatable tooth preparation for porcelain laminate veneers. *Pract Proced Aesthet Dent* 2003;15:17–24.
- Gürel G. Porcelain laminate veneers: minimal tooth preparation by design. *Dent Clin North Am* 2007;51:419–431.
- Granell-Ruiz M, Fons-Font A, Labaig-Rueda C, Martínez-González A, Román-Rodríguez JL, Solá-Ruiz MF. A clinical longitudinal study of 323 porcelain laminate veneers. Period of study from 3 to 11 years. *Med Oral Patol Oral Cir Bucal* 2010;15:e531–e537.
- Land MF, Hopp CD. Survival rates of all-ceramic systems differ by clinical indication and fabrication method. *J Evid Based Dent Pract* 2010;10:37–38.
- Friedman MJ. A 15-year review of porcelain veneer failure – A clinician's observations. *Compend Contin Educ Dent* 1998;19:625–630.
- Dumfahrt H, Schäffer H. Porcelain laminate veneers. A retrospective evaluation after 1 to 10 years of service: Part II – Clinical results. *Int J Prosthodont* 2000;13:9–18.
- Aristides GA, Dimitra B. Five-year clinical performance of porcelain laminate veneers. *Quintessence Int* 2002;33:185–189.
- Smales RJ, Etemadi S. Long-term survival of porcelain laminate veneers using two preparation designs: a retrospective study. *Int J Prosthodont* 2004;17:323–326.
- Fradeani M, Redemagni M, Corrado M. Porcelain laminate veneers: 6 to 12-year clinical evaluation – a retrospective study. *Int J Periodontics Restorative Dent* 2005;25:9–17.
- Aykor A, Ozel E. Five-year clinical evaluation of 300 teeth restored with porcelain laminate veneers using total-etch and a modified self-etch adhesive system. *Oper Dent* 2009;34:516–523.
- Valenti M, Valenti A. Retrospective survival analysis of 261 lithium disilicate crowns in a private general practice. *Quintessence Int* 2009;40:573–579.
- Radz GM. Minimum thickness anterior porcelain restorations. *Dent Clin North Am* 2011;55:353–370.
- Edelhoff D, Brix O. All-ceramic restorations in different indications: a case series. *J Am Dent Assoc* 2011;142(suppl 2):14S–19S.
- Edelhoff D, Sorensen JA. Tooth structure removal associated with various preparation designs for posterior teeth. *Int J Periodontics Restorative Dent* 2002;22:241–249.
- Amsterdam M, Rossman SR. Technique and hemisection of multirrooted teeth. *Alpha Omegan* 1960;53:4–15.
- Cortellini D, Canale A, Souza RO, Campos F, Lima JC, Özcan M. Durability and Weibull Characteristics of Lithium Disilicate Crowns Bonded on Abutments with Knife-Edge and Large Chamfer Finish Lines after Cyclic Loading. *J Prosthodont* 2015;23:615–619.

19. Cortellini D, Canale A. Bonding lithium disilicate ceramic to feather-edge tooth preparations: a minimally invasive treatment concept. *J Adhes Dent* 2012;14:7–10.
20. Valenti M, Valenti A. Retrospective survival analysis of 110 lithium-disilicate crowns with feather-edge marginal preparation. *Int J Esthet Dent* 2015;10:246–257.
21. Imburgia M, Canale A, Cortellini D, Maneschi M, Martucci C, Valenti M. Minimally invasive vertical preparation design for ceramic veneers. *Int J Esthet Dent* 2016;11:460–471.
22. National Code on Clinical Researches published in Official Gazette of the Turkish Medicines and Medical Devices Agency, number 28030, 13 April 2013.
23. Kırac FS. Is Ethics Approval Necessary for all Trials? A Clear but not Certain Process. *Mol Imaging Radionucl Ther* 2013;22:73–75.
24. Gürel G. *The Science and Art of Porcelain Laminate Veneers*. Chicago: Quintessence, 2003.
25. Larson TD. 25 years of veneering: What have we learned? *Northwest Dent* 2003;82:35–39.
26. Calamia JR, Calamia CS. Porcelain laminate veneers: reasons for 25 years of success. *Dent Clin North Am* 2007;51:399–417.
27. Dumfahrt H, Schäffer H. Porcelain laminate veneers. A retrospective evaluation after 1 to 10 years of service: Part II – Clinical results. *Int J Prosthodont* 2000;13:9–18.
28. Çötört HS, Dündar M, Öztürk B. The effect of various preparation designs on the survival of porcelain laminate veneers. *J Adhes Dent* 2009;11:405–411.
28. Sadowsky SJ. An overview of treatment considerations for esthetic restorations: A review of the literature. *J Prosthet Dent* 2006;96:433–442.
30. Peumans M, Van Meerbeek B. Porcelain veneers: a review of the literature. *J Dent* 2000;28:163–177.
32. Lacy AM, Wada C, Du W, Watanabe L. In vitro microleakage at the gingival margin of porcelain and resin veneers. *J Prosthet Dent* 1992;67:7–10.
33. Gürel G, Sesma N, Calamita MA, Coachman C, Morimoto S. Influence of enamel preservation on failure rates of porcelain laminate veneers. *Int J Periodontics Restorative Dent* 2013;33:31–39.
34. Guess PC, Stappert CF. Midterm results of a 5-year prospective clinical investigation of extended ceramic veneers. *Dent Mater* 2008;24:804–813.
35. Fradeani M. Six-year follow-up with Empress veneers. *Int J Periodontics Restorative Dent* 1998;18:216–225.
36. McLaren EA, Whiteman YY. Ceramics: Rationale for material selection. *Compend Contin Educ Dent* 2010;31:666–668, 670, 672.
37. Petridis HP, Zekeridou A, Malliari M, Tortopidis D, Koidis P. Survival of ceramic veneers made of different materials after a minimum follow-up period of five years: a systematic review and meta-analysis. *Eur J Esthet Dent* 2012;7:138–152.
38. Morimoto S, Albanesi RB, Sesma N, Agra CM, Braga MM. Main Clinical Outcomes of Feldspathic Porcelain and Glass-Ceramic Laminate Veneers: A Systematic Review and Meta-Analysis of Survival and Complication Rates. *Int J Prosthodont* 2016;29:38–49.
39. Layton D, Clarke M. A systematic review and meta-analysis of the survival of non-feldspathic porcelain veneers over 5 and 10 years. *Int J Prosthodont* 2013;26:111–124.
40. Burke FJ, Fleming GJ, Nathanson D, Marquis PM. Are adhesive technologies needed to support ceramics? An assessment of the current evidence. *J Adhes Dent* 2002;4:7–22.